

# Mucormycosis in changed Circumstances: Unabated Scourge of an Ongoing Covid19 pandemic in India

Dr Jagdish Chander

Departments of Microbiology

Govt Medical College Hospital, Chandigarh, India



## Introduction

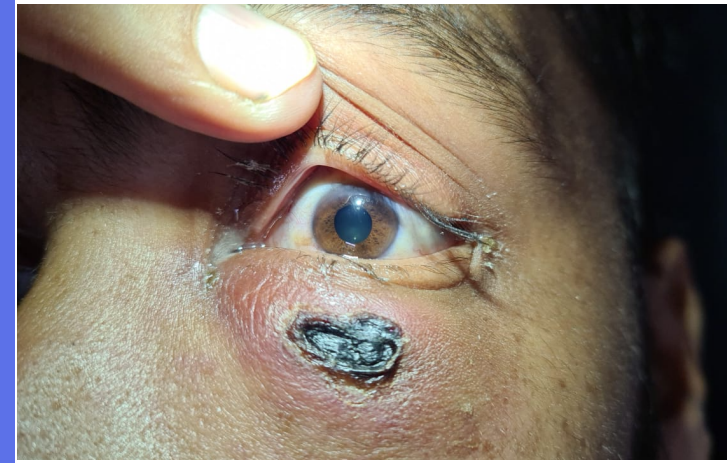
- Emerging and devastating infection, Mucormycosis, acute angio-invasive clinical entity caused by fungi belonging to Order Mucorales.
- Third most common opportunistic fungal infection after candidiasis and aspergillosis during this Covid19 pandemic called as CAM.
- Categorized into 6 clinical types: rhino-orbito-cerebral, pulmonary, cutaneous, gastrointestinal, disseminated and isolated renal mucormycosis.
- Fast growing aseptate hyphae, invade blood vessels entailing infarction and local necrosis.
- In developing countries like India, it is seen mainly in uncontrolled diabetes mellitus, whereas in developed countries it is seen hematological malignancy patients.
- The study was conducted over ten months from March 1, 2021 to December 31, 2021 (Second Wave) to understand extent of clinico-epidemiological profile of the ongoing Covid19 pandemic in a tertiary care north Indian hospital vis-à-vis Mucormycosis (CAM).
- During this second wave, India faced a major spate of mucormycosis among SARS-CoV-2 affected patients, popularly called as “black fungus”, reporting a total of 51,775 patients.

## Patients & Methods

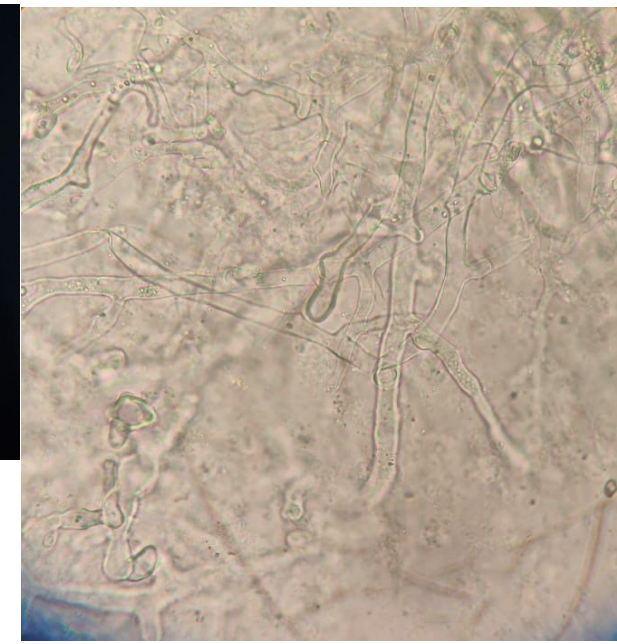- Nasal crust in rhino-orbito-cerebral, sputum/BAL in pulmonary, necrotic tissue in cutaneous and intestinal biopsy in GIT infection were processed for mycological etiology.
- Direct demonstration : KOH/CFW wet mounts.
- Histopathology : H&E, PAS and GMS stains.
- Fungal culture : SDA, blood agar, BHIA
- Morphological identification : lactophenol cotton blue mount (speciate Mucorale isolates)
- Further identification of isolates : sequencing of ITS region, comparing with those of type strains.

## Results

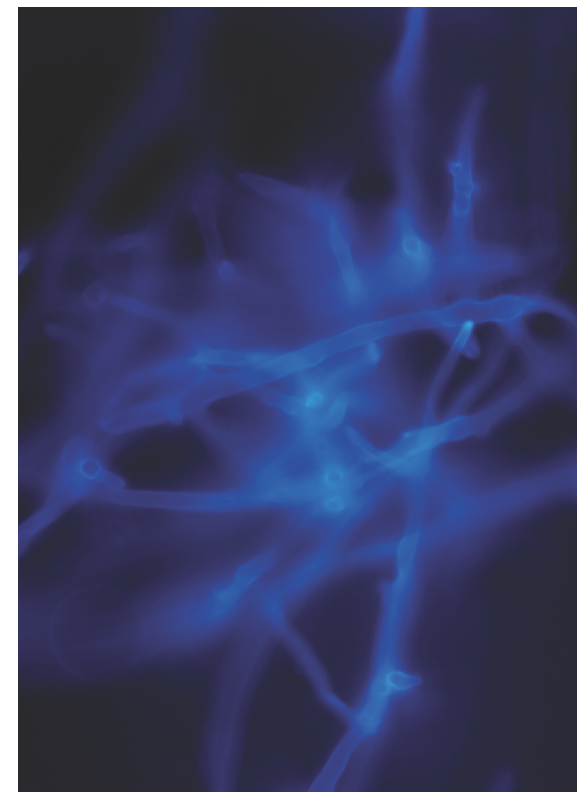
- A total of 143 cases of mucormycosis were reported during this 10 months period, 70 positive for Covid19 and 73 were negative based on the RT-PCR.
- Of these, 88 were males and 55 were females.
- Most common presentation was rhino-orbito-cerebral, followed by cutaneous, pulmonary, ocular and gastric.
- Diabetes mellitus was the underlying risk factor in 93 cases and 50 were non-diabetic
- Isolates identified were *Rhizopus arrhizus* (132), *Rhizopus homothallicus* (6), *Apophysomyces variabilis* (3) and *Lichtheimia corymbifera* (2).
- One-third patients had mixed fungal infection (both aspergillosis and mucormycosis).
- All patients were treated with liposomal amphotericin B with extensive surgical debridement.
- CAM patients reporting in advanced stage of Covid19 died due to complications of diabetes mellitus and other co-morbidities. Reporting during initial stage got saved and discharged



Black Eschar


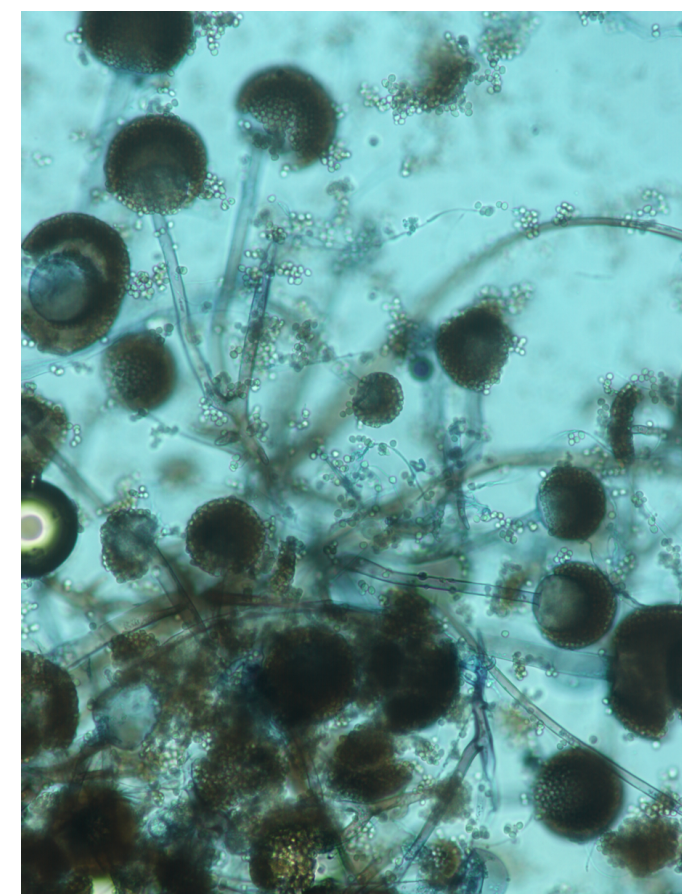


KOH Wet Mount



CFW Wet Mount

*Rhizopus arrhizus* growth & LCB



## Discussion

- CAM is a growing menace in tropical and sub-tropical Asian countries, which provides potential environmental niche for the survival of these fungi.
- Now, India is being termed as the diabetic capital of the world with an exponential increase in susceptible population, mucormycosis is also being encountered at an alarmingly increasing level and Covid19 has precipitated the situation.
- It is a life-threatening condition invariably proves to be fatal in a short span of time particularly during the Covid19 pandemic.
- Hence an early diagnosis, reversal of underlying risk factors, prompt institution of appropriate antifungal therapy and extensive surgical debridement are the key maneuvers for an appropriate management.
- The battle with this dreaded infection continues and should never be given up to save the population at risk of DM and Covid19.

## References

1. Chander J. Textbook of Medical Mycology. 4<sup>th</sup> edn. New Delhi: Jaypee Publishers, 2018.
2. Garg D, Muthu V, Sehgal IS, et al. Coronavirus Disease (COVID-19) associated mucormycosis (CAM): Case report and systematic review of literature. Mycopathologia 2021;186: 289-98.
3. Szarpak L, Chirico F, Pruc M, et al. Mucormycosis - A serious threat in the COVID-19 pandemic? J Infect 2021;83:237-79.
4. Chander J. Gastrointestinal Mucormycosis: A Challenge during COVID-19 Pandemic. J Gastrointest Infect 2021; 11: 30-35.