

Nguyen Thi Bich Ngoc^{1,2}, Le Ngoc Huy¹, Michel Pletschette³

¹Fungal Infections Center, Vietnam National Lung Hospital, Hanoi, Vietnam, ²Lung Department, University of Medicine and Pharmacy, Hanoi, Vietnam, ³Medical Center, The University of Munich, Munich, Germany

Introduction

Mucormycosis, a rare fungal infection has recently been diagnosed more frequently, also in relation with Covid-19. Pulmonary Mucormycosis, (PM) its second most common form is associated with an overall fatal rate over 50%. Currently, the diagnosis of PM relies on radiological and histopathological findings. Even though radiologic findings are mostly non-specific, they can have distinct features and are important to guide surgical biopsies for histopathological examinations. Here, we present the radiological findings of 6 mucormycosis cases seen in our hospital from January 2020 to September 2021 with emphasis on observations from High Resolution CT scans (HR-CT).

Methodology

We conducted an observational retrospective study for all Mucormycosis cases treated in Vietnam national Hospital over 18 months.

Result

All 6 cases showed damages to the lower- middle lobe more frequently seen at the left side than the right. The most common lesion was consolidation (ground glass opacity (GGO) at the early stage then changing to nodules and masses (i.e. necrotizing forms) with very large cavities developing with or without air-fluid levels. Pulmonary artery enlargement and pseudoaneurysms were seen in 2 cases associated with massive hemoptysis requiring embolization and lobectomy.

HR-CT findings

All the patients were admitted to hospital because of prolonged haemoptysis

- Most common comorbidity was diabetes type II
- Common damages includes: consolidation, cavities, GGO patterns.
- All the patients have been diagnosed based on histopathology

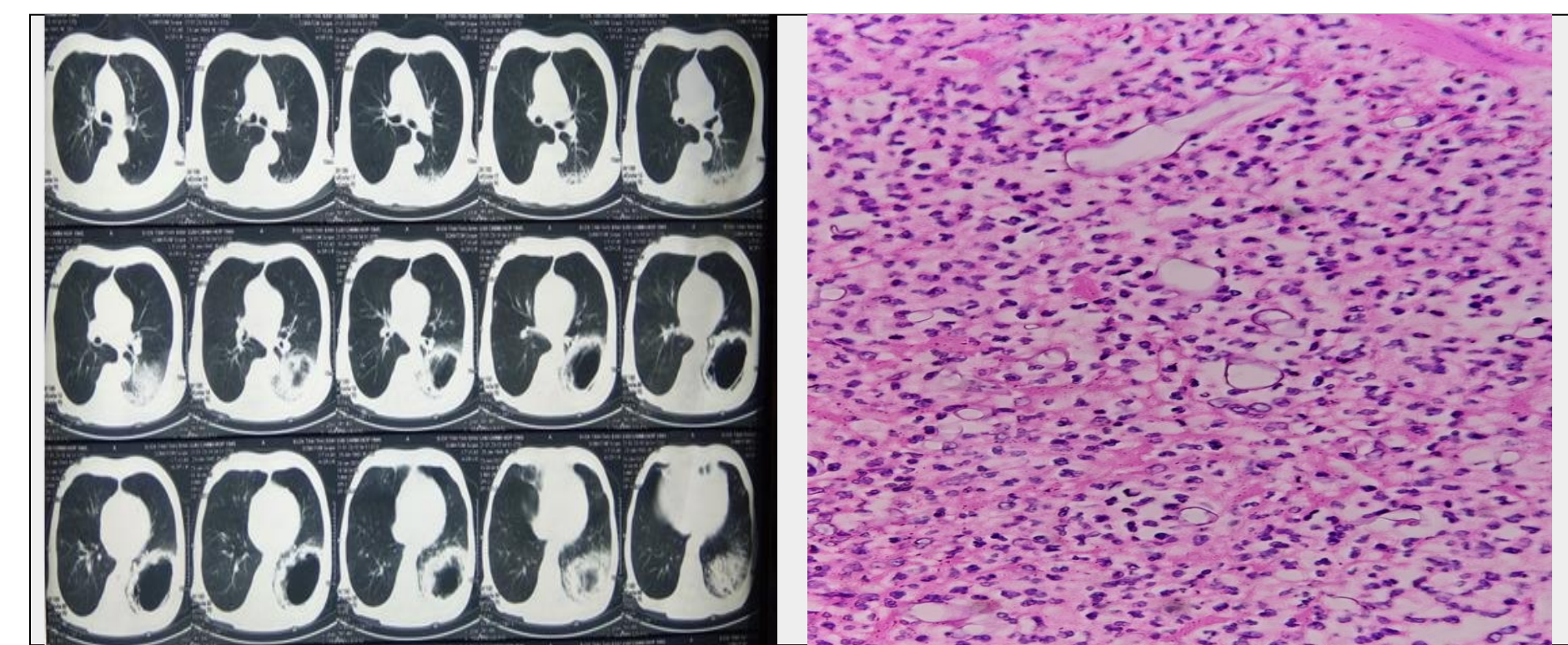


Figure 1. A 76-year-old male with diabetes type II. His CT-scan showed HR-CT show massive parenchymal damage (22x 39 mm) at the left lower lobe with pseudoaneurysms and bilateral bronchiectasis. The diagnosis of PM was based on histopathology.

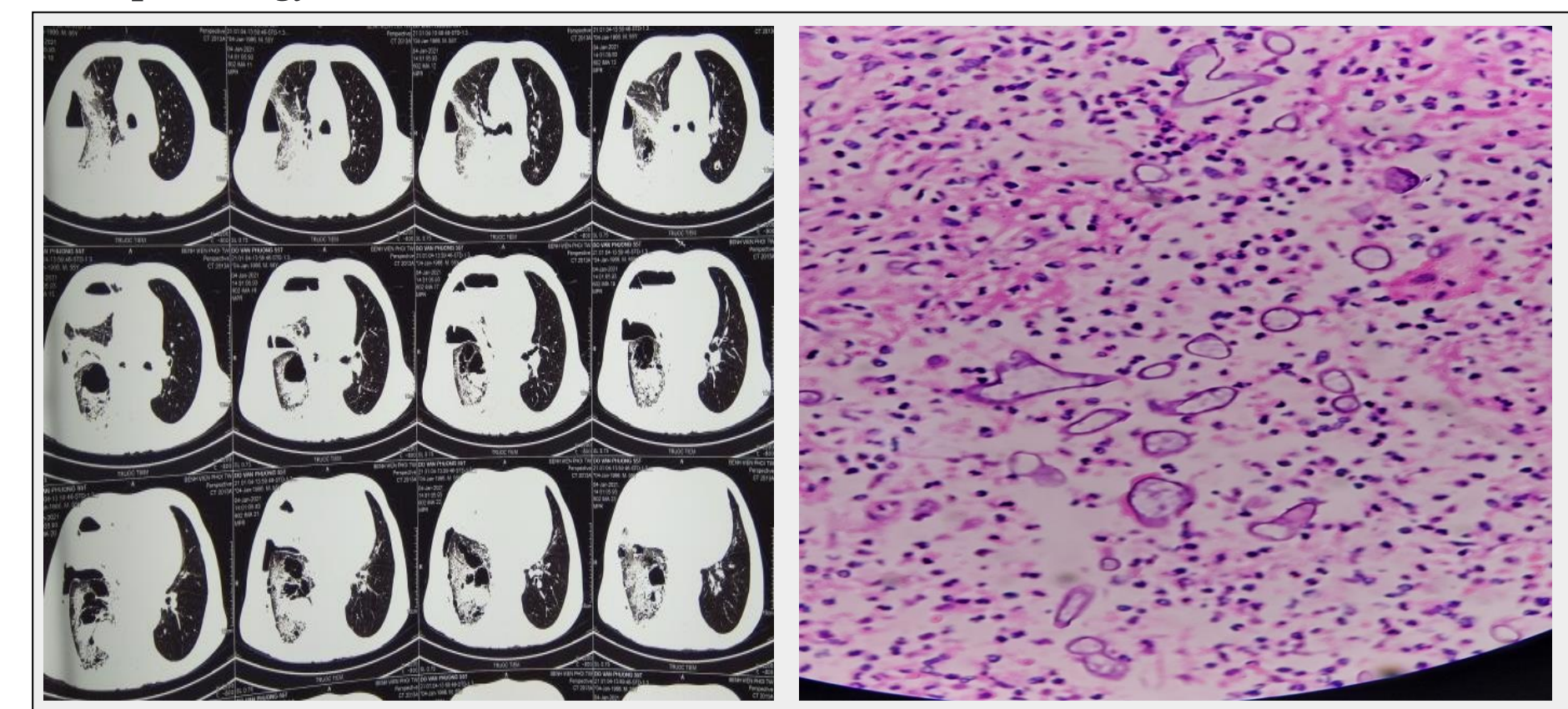


Figure 2: 55-year-old male, post TB, diabetes. His CT-scan showed GGO (ground glass opacities) with cavities with air/fluid level along with a pseudoaneurysm of the pulmonary artery and scattered opacities. The diagnosis of PM was based on histopathology.

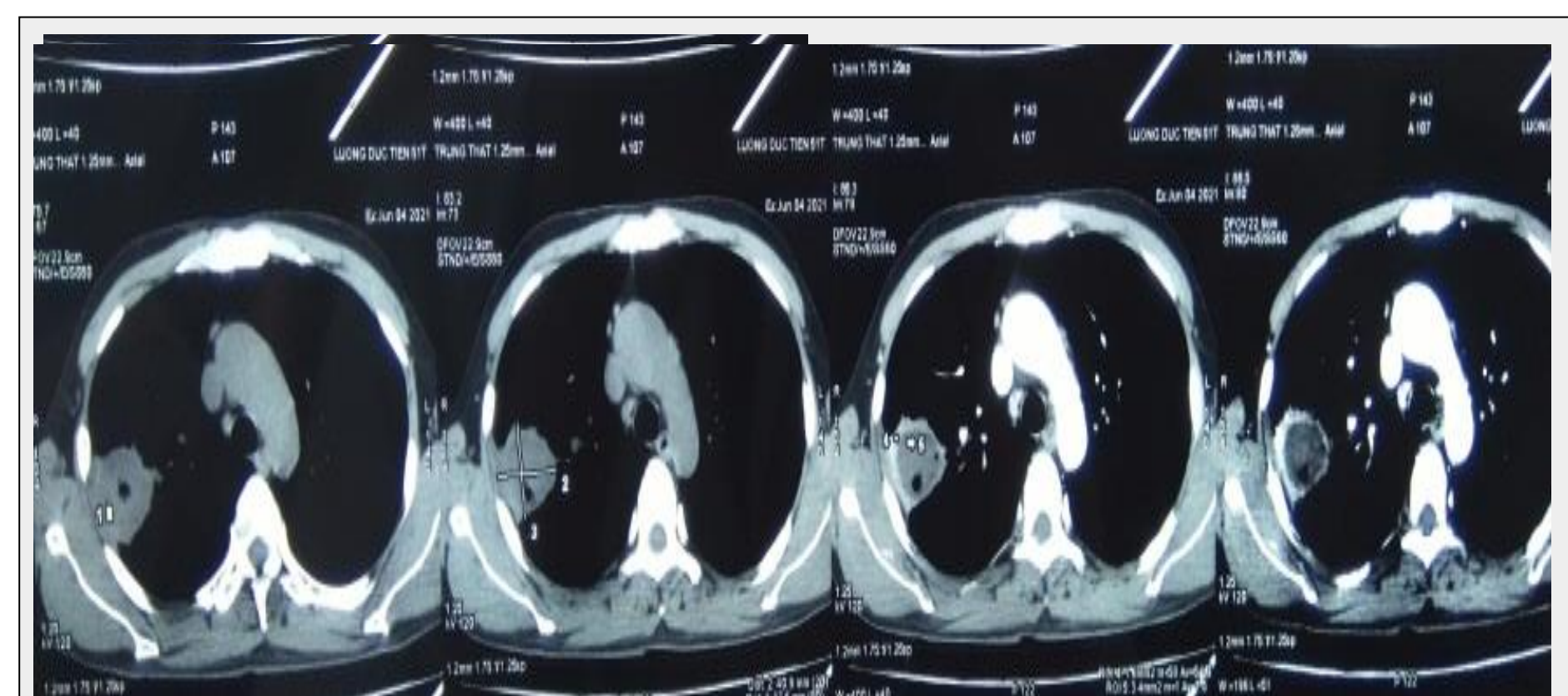


Figure 3: 51-year-old male patient with a history of M4 Leukemia. His CT scan found an abnormal mass 27 x 36 mm with cavity on the right upper lobe, multiple nodes bilateral. The diagnosis were concluded by lung biopsy.

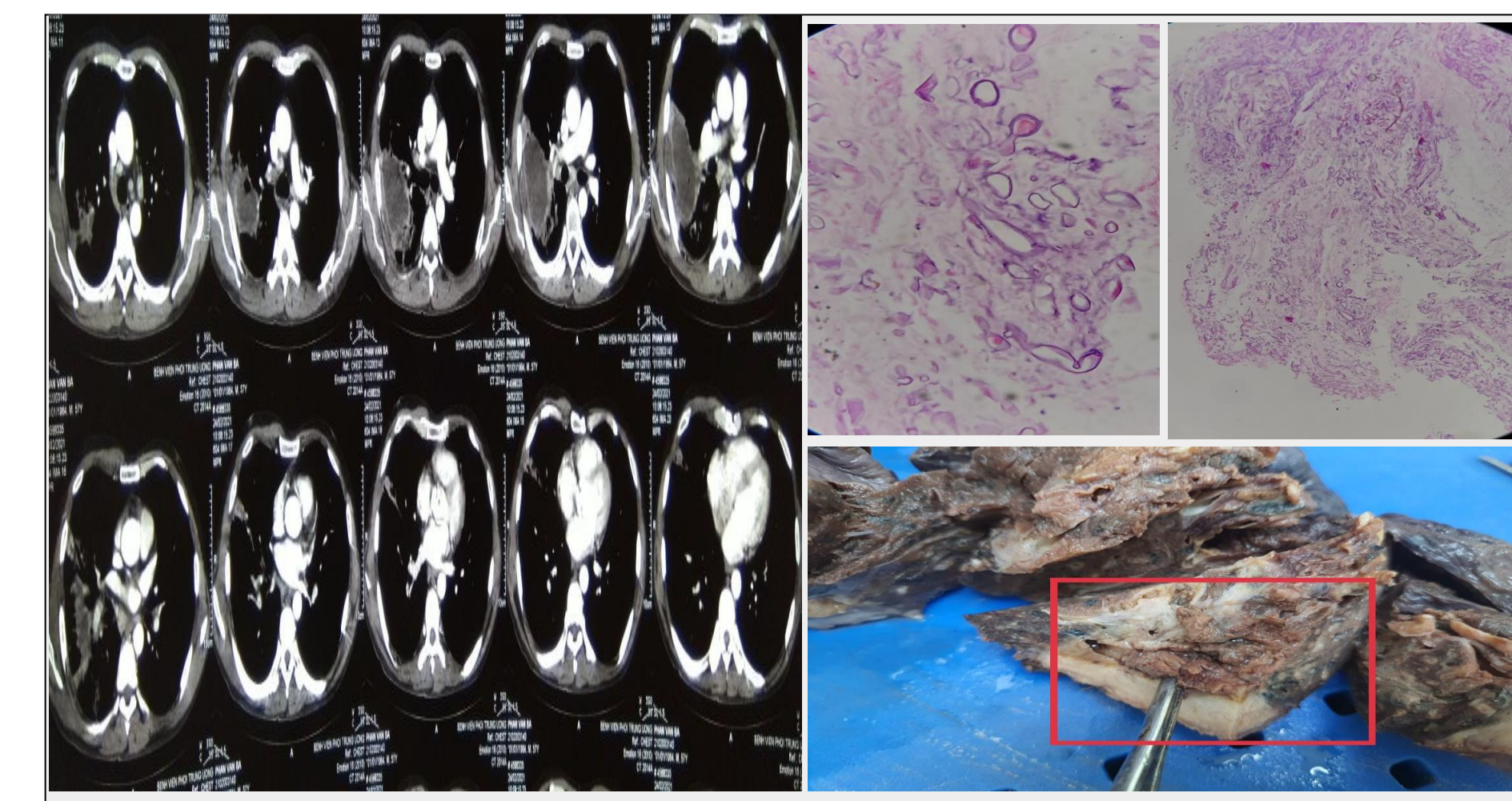


Figure 4. A 57-year-old male with no comorbidities. HR- CT demonstrated a consolidation right middle lobe, 74 x 107 mm, air-fluids level and necrotizing areas. The diagnosis of PM was based on histopathology (transbronchial biopsy and lobectomy)

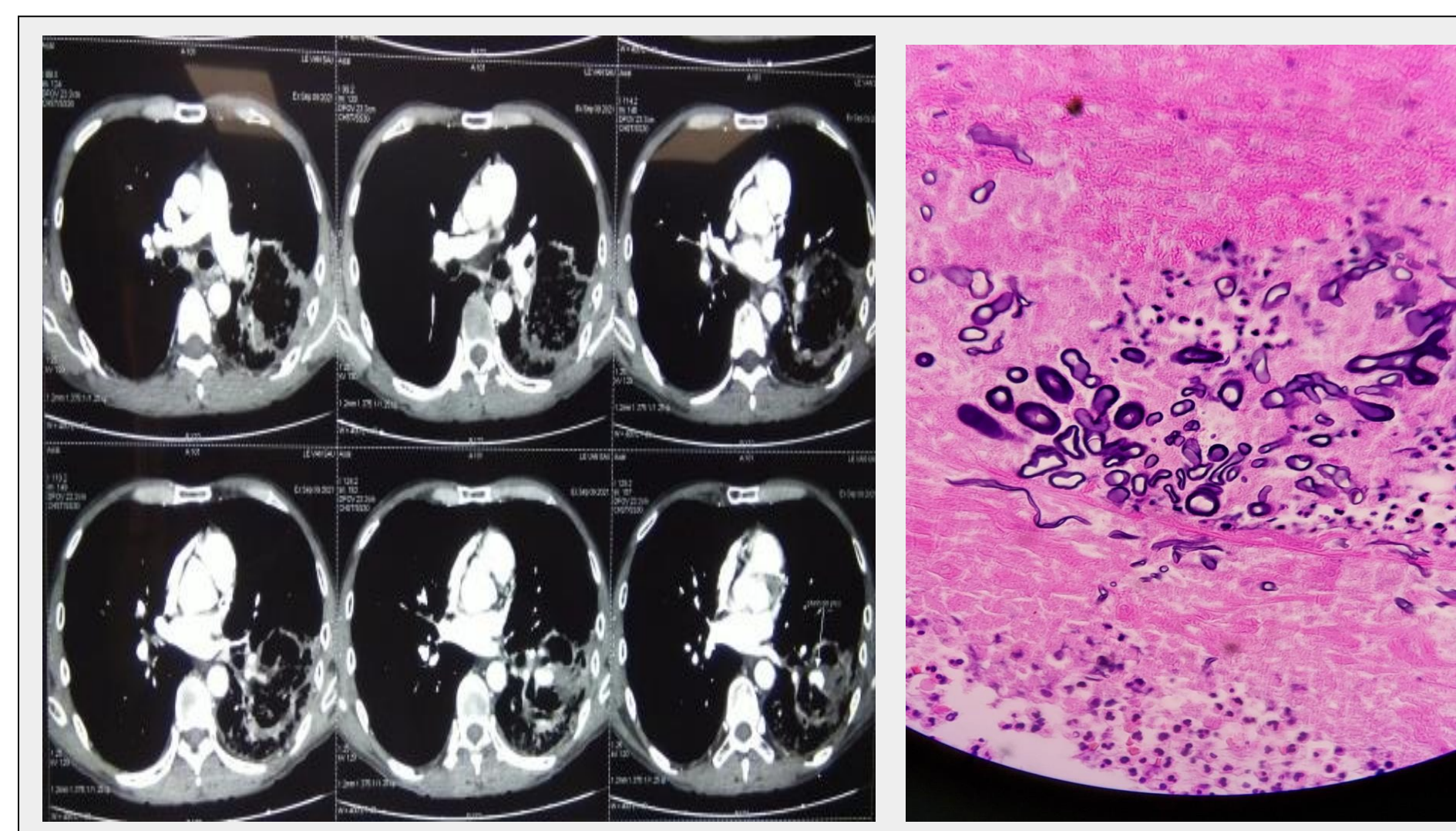


Figure 5. A 48-year-old male with a history of alcohol-abuse and hepatitis B. His CT chest angiography revealed a huge cavity at left lower lobe. The diagnosis of PM was based on histopathology.

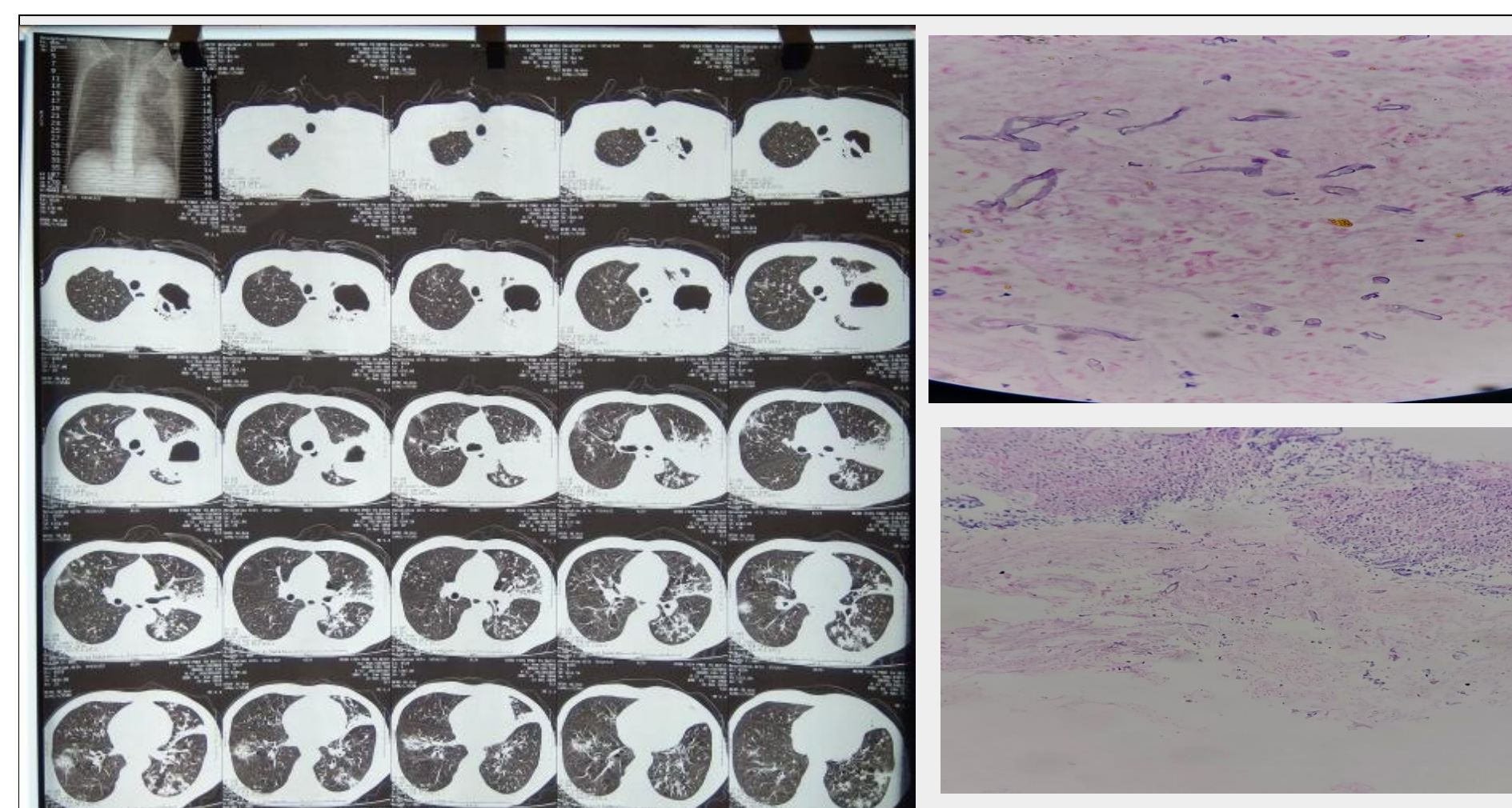


Figure 6. A 52-year-old male with chronic hepatitis B and diabetes. The CT scan of the thoracic demonstrated the appearance of necrotizing cavity 115 x 65 mm on the left upper lobe and bilateral nodes. .

Discussion

We presented imaging findings in a series of patients with pulmonary mucormycosis and identified additional imaging features along with the common reverse halo sign described in several previous studies. CT features include a large ground-glass halo, solid lesions, cavities and pseudoaneurysm. The massive ground- glass halo presumably represents hemorrhage while a huge GGO damage possibly indicates that mucormycosis causing larger pulmonary hemorrhages than other angio-invasive infections, such as Aspergillus sp. infections.

We also discovered cavitation and abnormal masses in some patients, whereas other patients went on to develop a multifocal pneumonia pattern. This pattern can mimic bacterial pneumonia; thus, in critically ill immunocompromised patients, fungal pneumonia—particularly mucormycosis—should be considered in the differential diagnosis of multifocal airspace disease particularly if a reverse halo sign is present. This appearance was associated with high mortality in our series (80%) and may reflect progressive fungal infection as the host immune system deteriorates

Conclusion

We present high quality radiological findings in PM are not fundamentally different from those seen in other fungal infections such as Aspergillosis, yet appear more massive . HR-CT scans can help to locate the involved site precisely and this information may be used as predictive factor for hemoptysis. Biopsy procedure remains the instrument of choice for prompt diagnosis and treatment.

References

1. Hammer MM, Madan R, Hatabu H. Pulmonary Mucormycosis: Radiologic Features at Presentation and Over Time. *AJR Am J Roentgenol* 2018;210(4):742–747.
2. Jung J, Kim MY, Lee HJ, et al. Comparison of computed tomographic findings in pulmonary mucormycosis and invasive pulmonary aspergillosis. *Clin Microbiol Infect* 2015;21(7):684.e11–684.e18
3. Agrawal R, Yeldandi A, Savas H, Parekh ND, Lombardi PJ, Hart EM. Pulmonary Mucormycosis: Risk Factors, Radiologic Findings, and Pathologic Correlation. *Radiographics*. 2020 May-Jun;40(3):656–666.
4. Denning DW, Cadanel J, Beigelman-Aubry C, Ader F, Chakrabarti A, Blot S, Ullmann AJ, Dimopoulos G, Lange C; European Society for Clinical Microbiology and Infectious Diseases and European Respiratory Society. Chronic pulmonary aspergillosis: rationale and clinical guidelines for diagnosis and management. *Eur Respir J*. 2016 Jan;47(1):45–68.