Bone Marrow Transplantation, (1998) 21, 917–921
© 1998 Stockton Press All rights reserved 0268–3369/98 $12.00
http://www.stockton-press.co.uk/bmt

Comparison of an enzyme immunoassay and a latex agglutination system for the diagnosis of invasive aspergillosis in bone marrow transplant recipients

M Machetti[1], M Feasi[1], N Mordini[2], MT Van Lint[2], A Bacigalupo[2], JP Latgé[3], J Sarfati[3] and C Viscoli[1]

[1]*University of Genova, National Institute for Cancer Research, Genova, Italy;* [2]*Department of Haematology and Bone Marrow Transplant Unit, S Martino Hospital, Genova, Italy; and* [3]*The Aspergillus Laboratory, Pasteur Institute, Paris, France*

Summary:

The performance of two *Aspergillus* antigenemia systems, the sandwich enzyme-linked immunosorbent assay (ELISA), Platelia *Aspergillus* test, and the latex agglutination (LA), Pastorex *Aspergillus* test, in the diagnosis of invasive aspergillosis were compared by testing 364 serum samples from 22 bone marrow transplant (BMT) recipients. Sensitivity and specificity for the ELISA test were 60% and 82% respectively, *vs* 40% and 94% for the LA test. In the two patients found positive with both methods, the ELISA test became positive earlier than the LA test or remained positive after the LA test had become negative. These results encourage further evaluation of the Platelia *Aspergillus* test, to assess its role in the management of invasive aspergillosis in BMT patients.
Keywords: invasive aspergillosis; galactomannan; antigen detection

In recent years, considerable progress has been achieved in the management of bacterial and viral infections in bone marrow transplant (BMT) recipients. By contrast, little progress has been made in the management of fungal infections, especially aspergillosis.[1] This is probably due both to the frequent impossibility of obtaining a reliable diagnosis of aspergillosis at an early stage of the disease and to the relatively poor efficacy of the presently available antifungal armamentarium. As a result, indirect diagnostic methods have received considerable attention in order to overcome these limitations. So far, no method has proven sufficiently sensitive and specific to allow a diagnosis of aspergillosis at an early stage.[2] However, several authors have pointed out that this might be due, at least in part, to how the tests have been used in clinical practice and to the criteria adopted by clinicians in the interpretation of results.[2] A precommercial version of a sandwich enzyme-linked immunosorbent assay (ELISA) for detection of circulating galactomannan, a polysaccharide component of the fungal cell wall, has been recently described.[3] The test employs the same monoclonal antibody (MoAb) EB-A2 used in the latex agglutination (LA) test (Pastorex *Aspergillus*; Sanofi Diagnostic, Pasteur, France), but the ELISA system detects galactomannan in serum at a concentration of 1 ng/ml, whereas the LA test has a 15 ng/ml threshold.

We have compared sensitivity and specificity of the new ELISA detection system with that of the LA system in the diagnosis of invasive aspergillosis in BMT patients. With the aim of improving the sensitivity and the specificity of the tests, we prospectively collected consecutive serum samples in patients at high risk of aspergillosis, regardless of the presence or absence of clinical symptoms.

Patients and methods

During a 6-month period, 22 allogeneic BMTs from matched donors, followed at the Bone Marrow Transplant Unit of the Haematology Department of San Martino Hospital in Genoa (Italy), were surveyed from the day of transplant (day 0) to day 90 after transplant for the development of signs and symptoms suggestive of invasive aspergillosis. Briefly, patients were hospitalized in single rooms without laminar air flow, in a standard unit equipped with HEPA filters, under strict isolation conditions. No routine microbiological surveillance cultures were taken. Patients ate cooked food and all items entering the room were sterilized. Persons entering the room were required to carefully wash their hands, and wore sterile gowns and masks. Patients received systemic antibacterial and antifungal prophylaxis with pefloxacin and fluconazole throughout the period of neutropenia. When fever developed (as occurred in all patients), a thorough evaluation was performed, including a physical examination and blood cultures. At this time antibacterial prophylaxis was stopped and a combination of ceftazidime and amikacin was started, in some cases with the early addition of vancomycin after 24–48 h. After 5 days of treatment, patients without any documented infection were given empirical amphotericin B, and prophylactic fluconazole was discontinued. Antibiotic and antifungal therapy was continued until bone marrow engraftment. After engraftment, patients were discharged from the HEPA filtered ward and either sent home and followed as

Correspondence: C Viscoli, Unità di Malattie dell'Ospite Compromesso, Istituto Nazionale per la Ricerca sul Cancro-Genova, Largo Rosanna Benzi, 10–16132 Genova, Italy
Received 22 May 1997; accepted 17 December 1997

outpatients or hospitalized in a standard ward in double rooms. In theory, no antibiotic prophylaxis should have been given to these patients. However, for various reasons most of them were actually receiving some sort of antibacterial and/or antifungal (fluconazole) prophylaxis. Both during and after neutropenia, patients were continuously surveyed for the development of respiratory signs and symptoms. In cases of fever or other symptoms suggestive of infection, cultures were taken (including a nasal swab and sputum culture, if clinically indicated) and chest X-rays were performed, followed by pulmonary CT scan if symptoms persisted. If a lesion was detected, bronchoalveolar lavage (BAL) was performed.

Based on clinical, radiological, histological and culture data, patients were classified into four groups: those who did not have any sign or symptom of aspergillosis and those with possible, probable and proven aspergillosis. Possible aspergillosis was defined as the presence of fever of unknown origin (>38°C) lasting for more than 5 days, respiratory symptoms (dyspnea, pleural chest pain), and either the presence of nonspecific pulmonary infiltrates with a negative BAL culture or *Aspergillus* sp. isolated from a nasal swab. Probable aspergillosis was defined as the presence of fever of unknown origin in a patient with a typical pulmonary lesion (triangular lesion with the base at the pleural side and apex at the hilum, surrounded by the 'halo sign' and/or showing initial or advanced cavitation), but with negative cultures and histological data unavailable. Proven aspergillosis was defined as the recovery of septate hyphae with acute angle branching consistent with *Aspergillus* and a compatible clinical presentation. Culture confirmation was not required.[4,5]

Serum samples were collected three times per week in the first month after BMT, and once a week in the second and third months. A total of 364 samples were collected and processed following the manufacturer's instructions. ELISA kits were kindly provided by Sanofi Diagnostic Pasteur, while the LA kits were purchased.

In all tests an appropriate positive control was included. For the ELISA test, all samples and controls were tested in duplicate.

For both tests, positivity was defined according to the manufacturer's instructions. For the LA test, every sample giving a positive result was immediately retested on a new aliquot of the same serum for confirmation. If confirmation was not obtained, the serum sample was considered negative. A single positive test was sufficient for defining a positive case. For the ELISA test, positivity was defined as the detection of at least two consecutive positive samples in a single patient. The difference in the definition of positivity between the two tests is due to the lower specificity of the ELISA with respect to the LA test.[6,7] The ELISA results were tabulated as the index between the optical density (OD) of the sample tested and the OD of the threshold positive control (index = 1). Samples with an index >1.5 were considered positive. Samples with an index between 1 and 1.5 were retested and considered positive only if the same index or higher was obtained.

Results

Table 1 reports the overall results of the study, with details on the type of documentation of aspergillosis (proven, probable and possible) when applicable, time from BMT to the first clinical sign, numbers of samples tested, results of the diagnostic tests (with numbers of positive samples and time to the first positive samples from BMT and from first clinical sign) and patient outcome. Among the 22 patients studied, five (23%) had invasive aspergillosis. There was one case of documented aspergillosis (No. 8), three cases of probable aspergillosis (Nos 6, 21 and 22) and one case of possible aspergillosis (No. 20). The patient with proven aspergillosis (No. 8) received a haploidentical, T-depleted BMT from his sister for an acute lymphoblastic leukaemia in its third remission. On day 10 after BMT, he developed generalized seizures, followed by sensory loss and coma. Repeated CT and MR imaging showed no parenchymal lesion. He died on day 45 after transplant. Autopsy revealed diffuse meningeal infiltration with hyaline acute branching septate, highly suggestive of meningeal aspergillosis and no other concomitant infection. He never had severe graft-versus-host disease (GVHD). The three patients with probable aspergillosis had typical pulmonary infiltrates. Patient No. 6 had acute lymphoblastic leukemia in first complete remission and received an allogeneic BMT from an HLA-identical donor. Pre-transplant sputum culture yielded *Aspergillus fumigatus*. On day 59 after transplant, concomitant with mild GVHD and positive CMV antigenemia, a CT scan showed pulmonary infiltrates, with a cavitating lesion. At this time he was febrile, but not neutropenic. Patient No. 21 had acute myeloid leukemia in first complete remission and received an allogeneic BMT from an HLA-identical donor. On day 46 after transplant, he became febrile and developed severe intestinal GVHD and CMV reactivation (positive antigenemia). CT scan showed subpleural nodules, compatible with a diagnosis of aspergillosis. Patient No. 22 had severe aplastic anemia and received an allogeneic BMT from an HLA-identical donor. Just before transplant (8 days), chest X-ray and CT scan showed bilateral infiltrates with no fever. At this time he was obviously severely neutropenic, but had no GVHD. The patient with possible aspergillosis received a haploidentical BMT from his sister for acute myeloid leukemia in second remisson, with severe marrow aplasia. He had persistent fever during severe neutropenia with a nasal swab positive for *Aspergillus*, but no evidence of sinusitis. Three of these patients (Nos 8, 21 and 22) tested positive on the ELISA test, while only two of them (Nos 8 and 22) were also positive on the LA test. Figure 1 shows the *Aspergillus* antigenemia results, as detected with both the ELISA and the LA test in the three above-mentioned patients that tested positive at the ELISA test. For each patient, the time of the first clinical sign of aspergillosis (fever, positive X-ray, positive CT scan or positive culture for *Aspergillus*) is also indicated. In the two patients who were positive on both tests, the ELISA always performed better than the LA. Indeed, patient No. 8 had all 16 samples positive with ELISA (100%), *vs* only 13 of 16 with LA (81%), and the ELISA was positive 7 days before the LA. Interestingly, in this patient ELISA test positivity preceded the first clinical

Table 1 Comparison of the ELISA and LA antigenemia results

Patient No.	*Type of diagnosis*	*Days from BMT to first clinical sign*	*No. samples tested*	*ELISA test*			*LA test*			*Outcome at the day 90 after BMT*
				No. positive samples	*Days from BMT to first positive sample*	*Days from clinical sign to first positive sample*	*No. positive samples*	*Days from BMT to first positive sample*	*Days from clinical sign to first positive sample*	
1	—		14							Died
2	—		20							Survived
3	—		15	2	26					Survived
4	—		5							Died
5	—		4							Died
6	Probable	59	16							Survived
7	—		21							Survived
8	Proven	5	16	16	0	–5	13	7	2	Died
9	—		20							Survived
10	—		19							Survived
11	—		20				1	4		Survived
12	—		20							Survived
13	—		20							Survived
14	—		23							Survived
15	—		23	7	19					Survived
16	—		20							Survived
17	—		21	2	19					Survived
18	—		19							Survived
19	—		22							Survived
20	Possible	–10	9							Died
21	Probable	46	5	2	67	21				Survived
22	Probable	–8	12	10	7	15	6	7	15	Survived

signs by 5 days and the OD index increased progressively until death (Figure 1a). Moreover, in this patient we tested a single cerebrospinal fluid sample, which was strongly positive with both the LA and the ELISA tests. Patient No. 22 had 12 samples tested, of which 10 (83%) were positive on the ELISA test *vs* only six (50%) on the LA test. In this patient, the ELISA test continued to give positive results until 1 month after the last positive latex test (Figure 1c). All positive results were consecutive, both with the ELISA and the LA test. Based on these results, sensitivity of ELISA and LA were 60% and 40%, respectively.

In the 17 patients without invasive aspergillosis the LA test performed better than the ELISA test. Patient No. 11 had a single sample (of the 20 studied) positive with the LA test, *vs* none with the ELISA. He had no clinical or radiological evidence of aspergillosis at any time, but coagulase-negative staphylococcal bacteremia was detected on the same day as the positive antigenemia. Patients Nos 3, 15 and 17 had two of 15, seven of 23 and two of 21 samples, respectively, positive with the ELISA test, *vs* none with the LA test. No sign of aspergillosis or possible cross-reactivity with any other organism in the blood was identified in these patients. Therefore, specificity was 82% for the ELISA test and 94% for the LA test.

Discussion

Invasive pulmonary aspergillosis is presently one of the leading causes of morbidity and mortality in BMT recipients, and it is considered to be the second cause of death, after relapse, in recipients of BMT from unrelated donors.[8] Diagnosis is always difficult in these patients.[9] Isolation of *Aspergillus* from sputum or bronchoalveolar lavage is partially unreliable, because *Aspergillus* is a ubiquitous organism and can be present in the human respiratory tract without causing disease. Documentation of aspergillosis requires the demonstration of acute angle branching septate hyphae invading tissues in biopsy specimens, possibly (but not necessarily) with cultural confirmation.[4,5] However, biopsy is frequently impossible because of the critical condition of the patient and because of severe concomitant thrombocytopenia. Since clinical symptoms and radiological signs are poorly specific, the disease is often suspected and treated empirically. In addition, when a lesion becomes radiologically detectable, it is probably too late for the treatment to be successful. For these reasons, indirect diagnostic methods (detection of antibodies, antigenic components and DNA fragments), have received considerable attention in the last decade, as a means of allowing early treatment and, hopefully, improved outcome.[2] Antibody detection seems to be unreliable because of the patient's inability to mount an effective antibody response. Detection of DNA fragments after amplification (PCR) is presently being studied, and clinical results are pending.[10,11]

Detection of cellular antigenic components has been studied extensively. Since the first report by Reiss and Lehmann,[12] several methods have been used to detect *Aspergillus* antigens in biological specimens (sera and urine) of patients with invasive aspergillosis.[13–21] Among all *Aspergillus* cellular products, galactomannan has been studied the most extensively and it has been shown to be

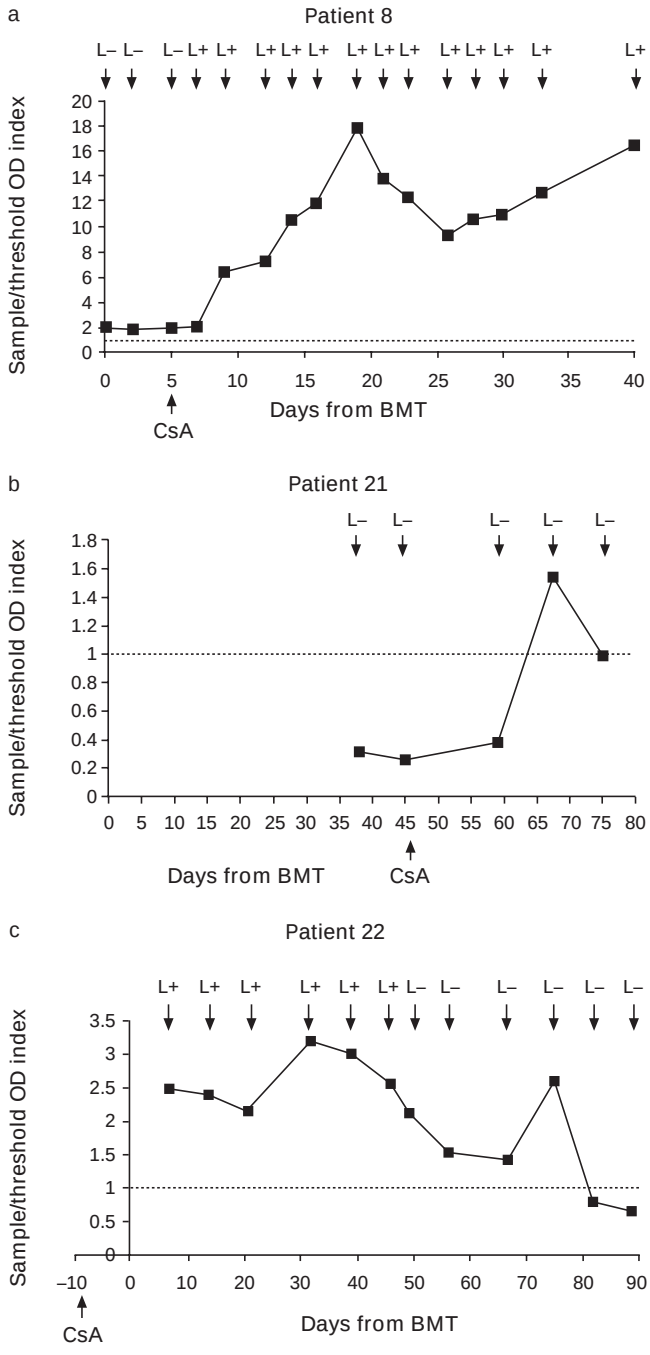

Figure 1 Follow-up of antigenemia by ELISA and LA test in patients Nos 8, 21 and 22. L+ = Latex test positive result; L– = Latex test negative result; CsA = clinical sign of Aspergillosis; —■— = Elisa test result; ----- = Elisa positivity threshold.

present in the sera of patients with invasive pulmonary aspergillosis.[12,13] Therefore, detection of galactomannan has been suggested as a possible diagnostic tool in patients with invasive aspergillosis.[14,17,22]

The Pastorex *Aspergillus* (LA) test has been widely investigated,[23–27] but its performance is controversial because of the wide range of sensitivity (38–95%) reported. In general, the test is considered not to be sensitive enough, although it has been suggested that sensitivity can be increased both by testing consecutive samples during the high risk period[23,28] and by sonicating the serum before testing.[29] However, specificity is usually considered good (90–100%). Indeed, in our study, we had only one false-positive specimen, concomitant with an episode of coagulase-negative staphylococcal bacteremia.

The ELISA test using the MoAb EB-A2 has been investigated in recent years,[3,6,7,11,30] and two previous studies which compared the ELISA and the LA tests using the MoAb EB-A2,[6,7] showed the ELISA to be more sensitive (82.5–90% *vs* 27.5–70%), but less specific (84–81% *vs* 86–100%) than the LA test. Two different hypotheses might be advanced as possible causes of the lower specificity of the ELISA test: (1) a transient antigenemia induced by immunosuppressive therapy; or (2) a cross-reactivity with unidentified components in serum.[7] Our study basically confirms previous findings, since the LA test was specific but of low sensitivity, and the ELISA test was more sensitive but slightly less specific. However, we found a slightly lower sensitivity with the ELISA test, with respect to previous studies.[6,7] This discrepancy might be explained by differences in the definition of aspergillosis. If we had not included cases of possible aspergillosis, as was done in the above-mentioned comparative studies,[6,7] the sensitivity would have improved (75% instead of 60%). Evaluation of the sensitivity of antigen-detection systems for the diagnosis of invasive fungal infections in immunocompromised patients may be influenced by the criteria used for defining a positive case. In this sense, it seems important to obtain a general consensus about how to define a case of aspergillosis for the evaluation of diagnostic tools.

Although the numbers are small, our study confirms that the ELISA test is more sensitive and less specific than the LA test. Moreover, it suggests that the test could be useful for the confirmation of the clinical suspicion of invasive aspergillosis in patients with a compatible illness and when histology or fresh smears show the presence of fungal hyphae in tissues or body fluids. Its performance must be more thoroughly evaluated, studying a larger number of cases.

Acknowledgements

We are grateful to Mrs Laura Veroni and to Mrs Mauri S Ulivi for their assistance in preparing the manuscript. The study was supported by an unrestricted educational grant from Pfizer, Rome, Italy. The Platelia Aspergillus antigen test was kindly provided by Sanofi Diagnostic Pasteur, Paris, France.

References

1 Armstrong D. Overview of invasive fungal infections and clinical presentation. In: Meunier F (ed). *Invasive Fungal Infections in Cancer Patients. Balliere's Clinical Infectious Diseases vol 2, No. 1*. Bailliere Tindall: London, 1995, pp 17–24.
2 Walsh TJ, Lyman CA, Pizzo PA. Laboratory diagnosis of invasive fungal infections in patients with neoplastic diseases. In: Meunier F (ed). *Invasive Fungal Infections in Cancer*

Patients. Balliere's Clinical Infectious Diseases vol 2, No. 1. Bailliere Tindall: London, 1995, pp 25–70.
3 Stynen D, Goris A, Sarfati J, Latge JP. A new sensitive sandwich enzyme-linked immunosorbent assay to detect galactofuran in patients with invasive aspergillosis. *J Clin Microbiol* 1995; **33**: 497–500.
4 Groll AH, Shah PM, Mentzel C *et al*. Trends in the post mortem epidemiology of invasive fungal infections at a university hospital. *J Infect* 1996; **33**: 23–32.
5 Schwartz J. The diagnosis of deep mycoses by morphologic methods. *Hum Pathol* 1982; **13**: 519–533.
6 Verweij PE, Stynen D, Rijs AJMM *et al*. Sandwich enzyme-linked immunosorbent assay compared with Pastorex latex agglutination test for diagnosing invasive aspergillosis in immunocompromised patients. *J Clin Microbiol* 1995; **33**: 1912–1914.
7 Sulahian A, Tabouret M, Ribaud P *et al*. Comparison of an enzyme immunoassay and latex agglutination test for detection of galactomannan in the diagnosis of invasive aspergillosis. *Eur J Clin Microbiol Infect Dis* 1996; **15**: 139–145.
8 Viscoli C, Boni L, Etzioni R *et al*. Infections in recipients of bone marrow transplant (BMT) from unrelated donors. 8th International Symposium on Infections in the Immunocompromised Host, 19–22 June 1994. Davos, Switzerland, 1994; (Abstr. 39).
9 Denning DW, Stevens DA. Antifungal and surgical treatment of invasive aspergillosis: review of 2121 published cases. *Rev Infect Dis* 1990; **12**: 1147–1201.
10 Melchers WJG, Verweij PE, van den Hurk P *et al*. General primer-mediated PCR for detection of *Aspergillus* species. *J Clin Microbiol* 1994; **32**: 1710–1717.
11 Verweij PE, Latge JP, Rijs AJMM *et al*. Comparison of antigen detection and PCR assay using bronchoalveolar lavage fluid for diagnosing invasive pulmonary aspergillosis in patients receiving treatment for hematological malignancies. *J Clin Microbiol* 1995; **33**: 3150–3153.
12 Reiss E, Lehmann PF. Galactomannan antigenemia in invasive aspergillosis. *Infect Immun* 1979; **25**: 357–365.
13 Dupont B, Huber M, Kim SJ, Bennett JE. Galactomannan antigenemia and antigenuria in aspergillosis: studies in patients and experimentally infected rabbits. *J Infect Dis* 1987; **155**: 1–11.
14 Rogers TR, Haynes KA, Barnes RA. Value of antigen detection in predicting invasive pulmonary aspergillosis. *Lancet* 1990; **336**: 1210–1213.
15 Patterson TF, Miniter P, Patterson JE *et al*. Aspergillosis antigen detection in the diagnosis of invasive aspergillosis. *J Infect Dis* 1995; **171**: 1553–1558.
16 Weiner MH. Antigenemia detected by radioimmunoassay in systemic aspergillosis. *Ann Intern Med* 1980; **92**: 793–796.
17 Talbot GH, Weiner MH, Gerson SL *et al*. Serodiagnosis of invasive aspergillosis in patients with hematologic malignancy: validation of the *Aspergillus fumigatus* antigen radioimmunoassay. *J Infect Dis* 1987; **155**: 12–27.
18 Sabetta JR, Miniter P, Andriole VT. The diagnosis of invasive aspergillosis by an enzyme-linked immunosorbent assay for circulating antigen. *J Infect Dis* 1985; **152**: 946–953.
19 Johnson TM, Kurup VP, Resnick A *et al*. Detection of circulating *Aspergillus fumigatus* antigen in bone marrow transplant patients. *J Lab Clin Med* 1989; **114**: 700–707.
20 Shaffer PJ, Kobayashi G, Medoff G. Demonstration of antigenemia in patients with invasive aspergillosis by solid phase (protein A-rich *Staphylococcus aureus*) radioimmunoassay. *Am J Med* 1979; **67**: 627–630.
21 Wilson EV, Hearn VM, Mackenzie DWR. Evaluation of a test to detect circulating *Aspergillus fumigatus* antigen in a survey of immunocompromised patients with proven or suspected invasive disease. *J Med Vet Mycol* 1987; **25**: 365–374.
22 Dupont B, Improvisi L, Provost F. Detection de galactomannane dans les aspergilloses invasives humaines et animales avec un test au latex. *Bull Soc Fr Mycol Med* 1990; **19**: 35–42.
23 Manso E, Montillo M, De Sio G *et al*. Value of antigen and antibody detection in the serological diagnosis of invasive aspergillosis in patients with hematological malignancies. *Eur J Clin Microbiol Infect Dis* 1994; **13**: 756–760.
24 Haynes K, Rogers TR. Retrospective evaluation of a latex agglutination test for diagnosis of invasive aspergillosis in immunocompromised patients. *Eur J Clin Microbiol Infect Dis* 1994; **13**: 670–674.
25 Ansorg R, Heintschel von Heinegg E, Rath PM. *Aspergillus* antigenuria compared to antigenemia in bone marrow transplant recipients. *Eur J Clin Microbiol Infect Dis* 1994; **13**: 582–589.
26 Warnock DW, Foot ABM, Johnson EM *et al*. *Aspergillus* antigen latex test for diagnosis of invasive aspergillosis. *Lancet* 1991; **338**: 1023–1024.
27 Hopwood V, Johnson EM, Cornish JM *et al*. Use of the Pastorex *Aspergillus* antigen latex agglutination test for the diagnosis of invasive aspergillosis. *J Clin Pathol* 1995; **48**: 210–213.
28 Van Cutsem J, Meulemans L, van Gerven F, Stynen D. Detection of circulating galactomannan by Pastorex *Aspergillus* in experimental invasive aspergillosis. *Mycoses* 1990; **33**: 61–69.
29 Grundy MA, Barnes RA, Coakley WT. Highly sensitive detection of fungal antigens by ultrasound-enhanced latex agglutination. *J Med Vet Mycol* 1995; **33**: 201–203.
30 Rohrlich P, Sarfati J, Mariani P *et al*. Prospective sandwich enzyme-linked immunosorbent assay for serum galactomannan: early predictive value and clinical use in invasive aspergillosis. *Pediatr Infect Dis J* 1996; **15**: 232–237.